

METROPOLITAN VETERINARY ASSOCIATES NEWSLETTER

VOLUME 5 ISSUE 2 • 2016 SUMMER EDITION

DR. JAMES DOUGHERTY RECEIVES LIFETIME ACHIEVEMENT AWARD

We are pleased to announce that Dr. James Dougherty has been named a 2016 Lifetime Achievement Award Winner by the Pennsylvania Veterinary Medical Association (PVMA). The award is given annually to a PVMA member who has demonstrated a lifetime of selfless dedication to veterinary medicine, the health and welfare of animals, and the betterment of the profession.

Thirty years ago, Dr. Dougherty co-founded Metropolitan Veterinary Associates & Emergency Services – creating the first multi-specialty referral hospital in the Philadelphia suburbs. His vision was to enhance and improve the lives of patients through a dedication to exceptional skill and extraordinary care. To achieve this vision, he worked to assemble a wide array of specialists in various disciplines to offer comprehensive diagnostic and treatment options. What began as a small, daytime specialty practice with just ten employees, has grown to a 25,000ft², state-of-the-art facility that operates 24/7/365, with over 140 team members representing a dozen areas of specialty practice.

“From our doctors and business office, to our facilities staff and nurses, our team is comprised of some of the most passionate, hard working people I know, and I dedicate this award to them” said Dr. Dougherty.

Dr. Dougherty is a Philadelphia native who earned his B.A. in Biological Science and M.S. in Animal Science at Rutgers University. He graduated from the University of Pennsylvania School of Veterinary Medicine, and worked for a year at a general practice hospital before completing a Small Animal Medicine and Surgery internship and residency at the University of Pennsylvania. Dr. Dougherty, Dr. Jerry Northington, and Dr. Lynne Maletz then created an internal medicine referral service at a local surgical practice, before co-founding Metropolitan in 1986.

As a loyal Rutgers alumnus, Dr. Dougherty is highly involved with the University, sitting on a number of boards, advisory committees, and organizations. In addition to the time he devotes to Rutgers, Dr. Dougherty co-founded and is an active part of the Paws of Promise Foundation – a charitable organization that provides pet owners with small grants to help fund emergency care. He has also been a board member and supporter of various local animal rescues for many years.

Dr. Dougherty not only helped create the premier emergency and specialty hospital in our area, he — along with Dr. Jon Nannos, Dr. Lori Cabell, and Dr. John DeBiasio — has curated an exceptional team of talented and dedicated doctors, nurses, and support



Dr. James Dougherty with dogs Liam and Declan.

staff. He consistently aspires to better the veterinary profession, and is a role model that others look up to and admire – both in the hospital, and throughout the community – exemplifying the values that the PVMA heralds with its Lifetime Achievement Award. 🐾

SPECIALIZED SERVICES

CARDIOLOGY

Michael Miller, MS, VMD, ABVP
Risa Roland, DVM, DACVIM (Cardiology)

DENTISTRY

Corinne Durand, DVM

DERMATOLOGY

Karen B. Farver, DVM, DACVD

EMERGENCY AND CRITICAL CARE

Reid Groman, DVM, DACVIM,
DACVECC
Allison Buysse, VMD
Jason Chamberlin, VMD
Robert Gaunt, VMD
Lydia Gentry, PhD, DVM
Jennifer McGough, VMD
Marisa Suvannevejh, VMD
Tracy Wu, VMD

INTERNAL MEDICINE

John V. DeBiasio, DVM, DACVIM
James F. Dougherty, MS, VMD
Leslie A. Kuczynski, VMD, DACVIM

INTERVENTIONAL RADIOLOGY

Risa Roland, DVM, DACVIM (Cardiology)

MINIMALLY INVASIVE SURGERY

Sherman O. Canapp Jr., DVM, MS,
CCRT, DACVS, DACVSMR
John V. DeBiasio, DVM, DACVIM
Leslie A. Kuczynski, VMD, DACVIM

NEUROLOGY

Melissa Logan, PhD, DVM, DACVIM
(Neurology)

ONCOLOGY

Suzanne Rau, DVM, DACVIM (Oncology)

OPHTHALMOLOGY

Amanda Corr, VMD, DACVO
Steven L. Gross, VMD, DACVO

RADIOLOGY

Robert McLearn, VMD, DACVR
Lisa Suslak, VMD, DACVR

SURGERY

Lori W. Cabell, DVM, DACVS
A. Jon Nannos, DVM
Jacqui Niles, BVETMED, SAS, DACVS
Catherine Popovitch, DVM, DACVS,
DECVS
Timothy M. Schwab, VMD, DACVS-SA
Rebecca Wolf, VMD, DACVS-SA

CEREBROVASCULAR ACCIDENTS IN VETERINARY MEDICINE

BY DR. MELISSA LOGAN | PHD, DVM, DACVIM (NEUROLOGY)

Cerebrovascular accidents (CVA) are increasing in recognition in veterinary medicine. A CVA, more commonly known as a “stroke” can be classified into two different groups. One type is secondary to obstruction of the blood vessels, leading to an infarction and the other type is due to rupture of the blood vessel and hemorrhage. In my experience, infarctions tend to be more common than hemorrhagic strokes in our patients. The prognosis for animals tends to be better than what is seen in humans due to the fact that animals do not have a prominent pyramidal system.

The brain requires a constant supply of oxygen and glucose due to the high energy consumption. The blood supply to the dog's brain is from the basilar and internal carotid arteries, while the cat's major supply is the maxillary artery. Any disease that affects this blood flow can lead to damage of the brain tissue and subsequent neurologic impairment.

“THERE IS A SPECIAL IMAGING SEQUENCE ON MRI CALLED GRADIENT ECHO (GRE) THAT CAN IDENTIFY HEMORRHAGE”

Unfortunately the brain relies solely on aerobic metabolism and does not have energy stores when blood supplies are not adequate. Cerebral blood flow requires 20% of the cardiac output and 15% of oxygen consumption in the resting state. This is disproportional to the fact that the brain itself only makes up 2% of the animals body weight.

Cerebral infarction can result from either disease of the arterial or venous system. In the larger vessels, a CVA can lead to a global infarction. If a small vessel is involved, this is considered a regional infarction.



The infarction is a result of an obstruction from either thrombosis of the vessel or due to an embolism. In many cases, there is an underlying metabolic or endocrine disorder that predisposes an animal to thrombosis. The most common causes include atherosclerosis from conditions like hypothyroidism, diabetes mellitus and hyperadrenocorticism. When dealing with embolic disease, the most common causes include sepsis, neoplasia, *Dirofilaria immitis*, and heart disease.

Cerebral hemorrhage is less common in our veterinary patients. It is classified as epidural, subdural, subarachnoid, intraparenchymal, or intraventricular. Essentially a hematoma is formed and creates a mass effect. The presence of the hematoma also induces edema, fluid accumulation and neuronal damage due to the release of osmotically active proteins that are released from the blood clot. Cerebral hemorrhage is classified into primary, such as due to hypertension, or secondary from neoplasia, coagulopathy, and even vascular malformations.

Clinical signs of a CVA include an acute onset of focal, asymmetric, and non progressive neurologic dysfunction. In some cases of hemorrhage, the signs can worsen over a period of time due to the mass

effect and edema. The neurologic signs will obviously depend on the location of the CVA. Disruption of blood flow in the cerebrum could lead to signs such as seizures, circling to the ipsilateral side, contralateral central blindness, contralateral proprioceptive deficits, and even head turns. In my experience, I commonly observe signs of vestibular dysfunction in animals with lesions in the thalamus and the brainstem. Obviously other cranial nerve abnormalities may be detected depending on the location of the CVA.

There is a subset of CVA that have clinical signs that are short lived and these are called transient ischemic attacks (TIAs). These are considered transient in that the signs resolve within 24 hours of onset. In my experience, I feel these animals present with acute vestibular dysfunction that resolves in many cases very quickly. Although the signs are short lived, the concern is that a TIA may make an animal at higher risk for a more profound CVA or global ischemic event.

Diagnosis of a CVA is typically made through MRI or CT imaging and clinical suspicion. CT can detect ischemia and infarction, as well as hemorrhage. That being said, MRI is more sensitive in evaluating for smaller lesions and the detection of edema. The lesions with cerebral infarction appear as well-demarcated regions with mild to no mass effect. Obviously hemorrhagic lesions can be expansile

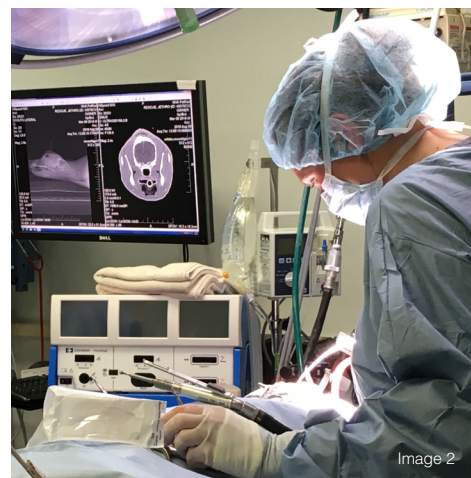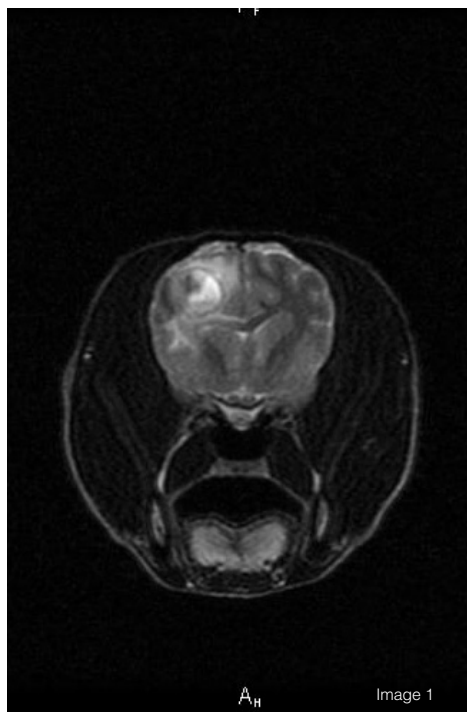


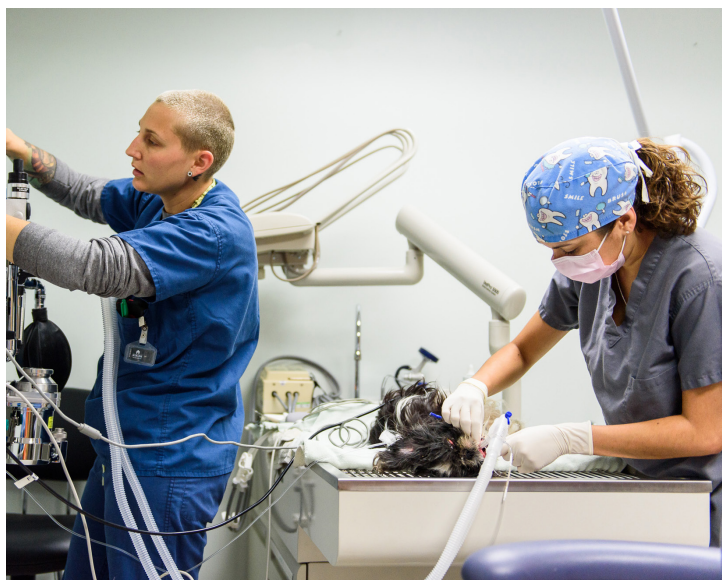Image 1: T2 weighted MRI image of a dog brain reveal a mass lesion (consistent with hemorrhage) in the left frontal/parietal lobe. This dog was diagnosed with thrombocytopenia (immune mediated) as was suspected to have intracranial hemorrhage.

Image 2: Dr. Melissa Logan performing a successful craniotomy on a puppy.

and have a mass effect noted on imaging. They can appear similar to a neoplastic lesion. There is a special imaging sequence on MRI called gradient echo (GRE) that can identify hemorrhage. There are also certain MRI characteristics of a hematoma over time. In addition to advanced imaging, baseline blood work as well as thyroid testing, urinalysis, coagulation profiles, and blood pressures are very useful in patients with a suspected CVA. This will help to discern for a potential underlying etiology for the CVA.

In a majority of cases however, an underlying etiology is not identified. This can be frustrating for the clients and the veterinarian alike.

There is no specific treatment for a CVA aside from treatment of the underlying etiology if identified. In cases of infarction, I have prescribed clopidogrel to help prevent additional CVAs in the future. This treatment is not necessarily proven to be effective, but in most cases carries little risk and minimal side effects. 🐾



OUR NEW DENTAL SUITE

Check out MVA's brand new dental suite! Dedicated solely to dental and oral surgery procedures, the 250ft² suite was expertly designed with the unique needs of oral surgery patients in mind. From a state of the art wet table to digital dental radiography and advanced instrumentation for periodontics, endodontics, prosthodontics, jaw fracture repair, and major oral surgery, our new dental suite ensures quality, personalized care for your pets. Oral surgeon Dr. Corinne Durand operates four days a week with consultations and same day procedures available, as well as emergency care. For more information or if you'd like a tour of our new space, give us a call at 610-666-1050 or email info@metro-vet.com. 🐾

UPCOMING CONTINUING EDUCATION EVENTS FROM METROPOLITAN

TUESDAY, SEPTEMBER 13, 2016

VETERINARY PRACTICE MANAGEMENT

SPEAKER: Terence M. O'Neil, CPA, CVA of
Katz, Sapper & Miller, Indiana

THURSDAY, OCTOBER 6, 2016

MY PET FELL DOWN: IS IT SEIZURE OR SYNCOPE

SPEAKERS: Melissa Logan, PhD, DVM, DACVIM (Neurology)
and Risa Roland, DVM, DACVIM (Cardiology)

VISIT METRO-VET.COM/CE FOR MORE INFORMATION & TO REGISTER



EMERGENCY
PET CARE
24/7/365
METRO-VET.COM

MVA WELCOMES THREE NEW ER VETERINARIANS



Pictured from left to right: Lydia Gentry, PhD., DVM; Allison Buysse, VMD; and Tracy Wu, VMD