

A newsletter  
for referring  
veterinarians

FALL 2009



# METROPOLITAN VETERINARY ASSOCIATES

Providing emergency care & specialized veterinary services

## INSIDE:

p2

Pulmonary Artery  
Hypertension

p3

Continuing Education

p4

Pet Loss Support Group

p4

Monthly Lecture Series

p4

Red Flags Rule



## WELCOME TO the first edition of our newsletter

**Established in 1986, Metropolitan Veterinary Associates & Emergency Services is a veterinary group that provides referral veterinary services.** We concentrate on specialty and emergency cases, allowing us to dedicate high-level care to the following disciplines: behavior, cardiology, dentistry, dermatology, emergency, internal medicine, neurology, ophthalmology, radiology (including CT and MRI) and surgery.

In order to maintain a high level of patient care, MVA moved into a newly renovated 18,000 square foot facility with state-of-the-art diagnostic and therapeutic equipment in 2006. If you haven't been able to visit our practice, we hope you can join us at one of the upcoming hospital lectures mentioned on page 4.

Please enjoy this newsletter and let us know of any topics of interest you'd like to see explored in future editions.

We've made it easier to contact us.

Catch us **24 HOURS A DAY** at **610/666/1050!**

(our primary phone number)

# DID YOU KNOW?

### Behavior

Laurie Bergman, VMD, ACVB

### Cardiology

Micheal Miller, MS, VMD, ABVP  
Risa Roland, DVM, ACVIM  
(Cardiology)

### Dentistry

Paul Orsini, DVM, ACVS.AVDC

### Dermatology

Karen B. Farver, DVM, ACVD

### Emergency Services

James Buckman, VMD, PhD  
Franciszek von Esse, VMD, ABVP  
Owen Fink, DVM  
Hilary H. Fordyce, VMD  
Jennifer McGough, VMD  
Marisa Suvannavejh, VMD  
Ryan Wheeler, DVM

Julie Banyacski, CVT, VTS (ECC)  
*Practice Manager*

### Internal Medicine

James F. Dougherty, MS, VMD  
John DeBiasio, DVM, ACVIM  
Damon B Rodriguez, DVM, ACVIM

### Neurology

Jerry W. Northington, DVM

### Ophthalmology

Stephen L. Gross, VMD, AVCO

### Radiology

Robert C. McLear, VMD, ACVR

### Surgery

Lori W. Cabell, DVM, ACVS  
A. Jon Nannos, DVM  
Jacqui Niles, BVetMed, SAS, ACVS  
Catherine Popovitch, DVM, ACVS  
Timothy M. Schwab, VMD, Resident



# PULMONARY ARTERY HYPERTENSION

## RISA ROLAND, DVM, DACVIM (CARDIOLOGY)

**Pulmonary artery hypertension (PAH) refers to an increase in the pressure in the pulmonary arterial tree. Although once thought to be exceptionally rare, knowledge of its associated clinical signs as well as advances in diagnostic tests have helped reveal it to be relatively common. PAH results from reduction in the caliber of the pulmonary vessels and/or increases in pulmonary blood flow. It is of importance clinically as it contributes significantly to patient morbidity and mortality.**

PAH is classified as occurring either primarily (i.e. due to an essential increase in the blood pressure in the pulmonary arteries) or secondary to other diseases (e.g. pulmonary venous hypertension, respiratory diseases, chronic pulmonary thromboembolism, and disorders of the pulmonary vasculature). In human medicine, primary pulmonary hypertension occurs as a familial trait. In veterinary medicine, PAH is most commonly secondary to other diseases. A common inciting condition is high pulmonary venous pressure which may occur as a result of high left atrial pressure. In the dog this is most commonly seen with chronic degenerative valve disease and dilated cardiomyopathy. Another secondary cause of PAH are respiratory disease including chronic tracheobronchitis, chronic pneumonia, and interstitial lung disease. Pulmonary thromboembolism can also lead to PAH and can occur secondary to any disease that leads to a hypercoagulable state. Examples of such diseases include Cushing's disease, pancreatitis, sepsis, neoplasia, protein-losing diseases, and coagulopathies. Heartworm disease can lead to pulmonary thromboembolism as well as changes in the pulmonary arteries themselves. Both of these changes lead to PAH.

Patients with significant PAH may present in a number of ways. In addition to the clinical signs associated with the primary disease that lead to the PAH, PAH itself may result in exercise intolerance, cough, respiratory difficulty, syncope and right-sided heart failure (ascites with jugular venous distension). Physical examination findings may reveal a right-sided systolic heart murmur due to tricuspid regurgitation, a stronger precordial impulse on the right side of the chest, a split S-2 heart sound, abnormal lung sounds related to underlying respiratory disease, jugular venous distension, ascites and any other findings associated with the primary disease. Diagnostics to determine if pulmonary hypertension is a possibility include chest radiographs as well as an echocardiogram. Chest radiographs may reveal right atrial and right ventricular enlargement, main pulmonary artery enlargement or peripheral pulmonary artery enlargement, and the presence of underlying lung disease. Echocardiographic results may reveal right atrial enlargement, right ventricular enlargement, a dilated main pulmonary artery, tricuspid regurgitation, pulmonic regurgitation and evidence of underlying heart disease. A tricuspid regurgitation velocity  $> 2.7$  m/s and/or a peak pulmonary insufficiency velocity  $> 2.2$  m/s (with normal transpulmonic velocities) are diagnostic for PAH.



However, the absence of these changes in velocity does not rule out PAH. Once pulmonary hypertension is confirmed and evidence of significant left atrial enlargement (suggesting primary cardiac disease as a cause) is not present on the echocardiogram, a search for an underlying cause is warranted.

Unfortunately there is no cure for PAH. Thus every attempt must be made to identify and reverse underlying primary disease. If reversal is not possible, aggressive treatment of the primary underlying disease is warranted. If the animal remains clinical for PAH despite treatment of the underlying disease, or if treatment of the underlying disease is not possible, the goal of treatment of PAH is to palliate clinical signs and prolong survival. In the acute setting, oxygen

is used as a potent pulmonary arterial dilator. Currently, there are novel therapeutics being used to help dilate the pulmonary arteries; the most commonly used is sildenafil, a phosphodiesterase 5 inhibitor. If right heart failure has occurred, in addition to sildenafil, diuretics, angiotensin-converting enzyme inhibitors, pimobendan, and vasodilators may also be indicated. The long-term prognosis with PAH remains guarded but if the underlying disease can be controlled the PAH may reverse.

PAH is an important clinical sequelae to many primary veterinary disorders. As PAH leads to significant morbidity and mortality, diagnosis of PAH, treatment of the underlying cause and palliation of the clinical signs associated with PAH is prudent.

# CE ON 10/29/09 LEGAL SEA FOODS

King of Prussia :: 7:00 pm



OCTOBER 29, 2009

7:00 to 7:30pm

Dinner & Registration

7:30 to 9:30pm

Presentations

GENEROUSLY  
SPONSORED BY



LEGAL SEA FOODS

680 West Dekalb Pike  
King of Prussia, PA 19406

## METROPOLITAN VETERINARY ASSOCIATES AND THE SUBURBAN VETERINARY MEDICAL ASSOCIATION

CORDIALLY INVITE YOU TO ATTEND A DINNER PRESENTATION:

“Common Cardiac Interventional Procedures”

*Presented by Risa Roland, DVM, DACVIM (Cardiology)*

“Updates in the Management of Urolithiasis”

*Presented by Larry Adams, DVM, PhD, ACVIM*

RSVP

Stacey Connell

Call: 610/666/1050 or email: [sconnell@metro-vet.com](mailto:sconnell@metro-vet.com)  
Limited spaces available, so don't delay!

*Certificates for attending 2 hours of CE provided by the Suburban VMA*

## PET LOSS SUPPORT GROUP

Many of our employees have experienced and understand the depth of loss one experiences when a beloved four-legged family member has passed. For that reason, Metropolitan provides a pet loss support group to help grieving owners in need. Our pet group is designed to provide grieving pet parents with a safe, confidential environment to share their feelings with others who have experienced pet loss.

The meetings are held once a month onsite at Metropolitan and are free of charge for your clients (all family members are invited to attend). The group is led by Dr. Cari Thomson and co-led by psychiatrist Dr. Carol Tavani.

Please contact us at **610/666/1050** if you would like to have Pet Loss Support Group brochures mailed to your office. Clients are able to visit our website to find meeting dates and times, general information and recommendations on obtaining help outside of the group setting.

# JOIN US

## FOR OUR MONTHLY HOSPITAL LECTURES

DATE/TIME	PRESENTER/TOPIC
10/15/09/6pm	Dr. Jerry Northington Dementia
11/19/09/6pm	Dr. Risa Roland Pulmonary Hypertension
12/17/09/6pm	Dr. Ryan Wheeler Traumatic Brain Injury

All lectures will be held at Metropolitan  
Dinner provided :: Space is limited

**RSVP** Stacey Connell  
at **610/666/1050** or  
[sconnell@metro-vet.com](mailto:sconnell@metro-vet.com)



### RED FLAGS RULE

The FTC has **delayed** enforcement of its anti-identify-theft regulation, commonly known as the "Red Flags Rule" until **11/1/2009**. For help in putting together the program (including rolling out documents to your staff) please contact **Stacey Connell** at **610/666/1050** or [sconnell@metro-vet.com](mailto:sconnell@metro-vet.com). She's able to offer recommendations or provide necessary documents to help ensure compliance.

For more information please visit: [http://www.avma.org/issues/FTC\\_red\\_flags\\_rule.asp](http://www.avma.org/issues/FTC_red_flags_rule.asp)



### METROPOLITAN VETERINARY ASSOCIATES

2626 Van Buren Avenue • Norristown, PA 19403

tel 610/666/1050 fax 610/666/1199

website [www.metro-vet.com](http://www.metro-vet.com)



# SAFE MRI & HIGH QUALITY IMAGES

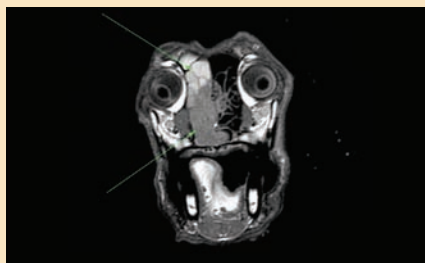
ADJACENT TO METROPOLITAN VETERINARY ASSOCIATE'S BUILDING



## FINALLY, A SAFE NON-INVASIVE DIAGNOSTIC TOOL AT YOUR DOORSTEP THAT CAN ANSWER THESE QUESTIONS:

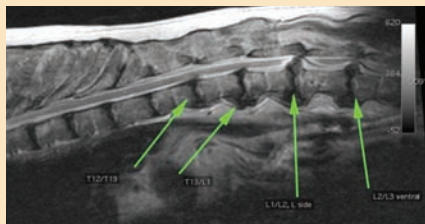
- 1) How can I obtain quality information to make good clinical decisions?
- 2) How can I help my owners obtain all the information they need?
- 3) How can I enhance my practice when dealing with patients that arrive with:
  - Ataxia
  - Trauma
  - Neurological symptoms
  - Paresis
  - Urinary control difficulties
  - Hind limb hypermetria
  - Cervical pain
  - Seizures
  - Oncology issues
  - Tetraparesis
  - Head tilt
  - Hind limb weakness
  - Lameness
  - Brain tumors

**ANSWER: DIAGNOSE WITH MRI AT VET IMAGING PARTNERS**



**7-Year-old Golden Retriever with left sided nasal bleeding over the past two months.**

Results: A left sided nasal cavity mass extending through the choana and slightly through to the right of midline within the nasal pharynx. Radiotherapy treatment was planned.



**9-Year-old German Shepherd with history of worsening neurological symptoms.**

Results: Severe spinal cord compression, levels L1/L2, L2/L3, caused by intervertebral disc herniation.

OUR RESULTS



**CALL US TODAY** to schedule your patient's MRI or to speak with our staff about how we can serve your practice and patients.

### COME MEET OUR DOCTORS

**ANESTHESIA:**  
Sandra Perkowski, VMD, PhD, Dipl ACVA

**RADIOLOGY:**  
Alexia McKnight, DVM, DACVR, McKnight Insight  
Robert C. McLearn, VMD, DACVR, PetRad

**CONTACT** : **877 DOG SCAN (877/364/7226)**  
**WWW.VETIMAGINGPARTNERS.COM**



## MEET OUR SPECIALISTS



**DR. JOHN DEBIASIO**

### **JOHN DeBIASIO DVM, ACVIM**

Our newest internal medicine specialist, Dr. John DeBiasio, joined the MVA family almost 1 year ago. Since that time, he has proved a valuable asset particularly with regard to assisting the emergency service with patients presenting with critical internal medicine related disorders. He provides both consultation to the emergency clinicians as well as direct management of these often complex and intensive cases. In addition, Dr. DeBiasio comes to MVA with extensive training in minimally invasive diagnostics most notably endoscopy and laparoscopy, the latter which he most commonly utilizes to obtain high quality liver biopsies. Although his interests are quite varied among the many disciplines that make up the specialty of internal medicine, he has a particular interest in gastrointestinal system and brings with him extensive experience from working in the Texas A&M Gastrointestinal Laboratory both on clinical and diagnostic research.



**DR. RISA ROLAND**

### **RISA ROLAND, DVM, DACVIM (CARDIOLOGY)**

A native of Brooklyn, New York, she attended Cornell University and obtained her Bachelor of Science degree with honors in animal science in 1998. She continued her education at Cornell University, School of Veterinary Medicine, and was awarded her Doctor of Veterinary Medicine degree in 2003. She completed an internship at the University of Pennsylvania, a cardiology residency program at Texas A&M University, and became board certified by the American College of Veterinary Internal Medicine in 2007.

Dr. Roland's particular interests include congenital abnormalities, chronic degenerative valve disease and cardiomyopathies. Dr. Roland performs numerous specialized procedures which include echocardiography, electrocardiography, pacemaker implantation, patent ductus arteriosus embolization, balloon valvuloplasty, diagnostic catheterization, portosystemic shunt embolization and heartworm retrieval.



**CALL US**  
**24 HOURS A DAY :: 610/666/1050**  
**VISIT US AT [WWW.METRO-VET.COM](http://WWW.METRO-VET.COM) TODAY**

**METROPOLITAN**  
**VETERINARY**  
**ASSOCIATES**